INDEX COPERNICUS INTERNATIONAL

ORIGINAL ARTICLE

Received: 13.10.2025
Accepted: 11.01.2026
Published: 29.04.2026

CITE THIS ARTICLE AS:
Ghosh S., Padia N.: Management protocol of invasive fungal sinusitis during COVID-19 pandemic; Otolaryngol Pol 2026; 80 (2): 14–22; DOI: 10.5604/01.3001.0055.6613

AUTHORS' CONTRIBUTION:
A. Conceptualization
B. Data Curation
C. Formal Analysis
D. Funding Acquisition
E. Investigation
F. Methodology
G. Project Administration

CORRESPONDING AUTHOR:
Dr. Neha Padia; Sri Sri Holistic Hospital, Kalajyothi Road, Masjid Banda Rd, next to Ryan International School, Sai Pruthvi Enclave; Kondapur, Hyderabad, Telangana 500084, India; Phone: +91 8722075623; E-mail: dr.nehapadia.ent@gmail.com

COPYRIGHT:
Some rights reserved: Polish Society of Otorhinolaryngologists Head and Neck Surgeons. Published by Index Copernicus Sp. z o.o.

OPEN ACCESS:
The content of the journal „Polish Society of Otorhinolaryngologists Head and Neck Surgeons" is circulated on the basis of the Open Access which means free and limitless access to scientific data.

CREATIVE COMMONS CC BY:
This material is available under the Creative Commons – Attribution NonCommercial 4.0 International (CC BY-NC 4.0). The full terms of this license are available on: https://creativecommons.org/licenses/by-nc/4.0/Legalcode

COMPETING INTERESTS:
The authors declare that they have no competing interests.

Management of COVID associated invasive fungal sinusitis

Sampurna Ghosh[1ABEF], Neha Padia[2CDEF]

[1]Medicover Hospitals, Hyderabad, Telangana, India
[2]Sri Sri Holistic Hospitals, Hyderabad, Telangana, India

ABSTRACT:

Introduction: Mucormycosis is a life-threatening infection caused by fungi belonging to the order *Mucorales*. *Aspergillus* and *Mucormycetes* have been reported as the principal fungal pathogens in patients with COVID-19. The main risk factors include uncontrolled diabetes mellitus and steroid use.

Aim: The current study aims to analyze the diagnostic indicators, treatment protocols, and follow-up approach in patients with post-COVID mucormycosis.

Material and methods: Patients who were admitted to Medicover Hospitals with acute sinusitis symptoms were included in the study. Data was collected using a structured proforma which included demographic details, past medical history, days of presentation from COVID-19 diagnosis, and ocular, nasal, and oral symptoms. We recorded the magnetic resonance imaging (MRI) and computed tomography (CT) findings and monitored blood parameters like total leukocyte count (TLC), C-reactive protein (CRP), erythrocyte sedimentation rate, glycated hemoglobin and creatinine. All patients were divided into stages and underwent relevant surgical procedures along with antifungal therapy. A follow-up was performed to assess for residual or recurrent disease and survival at 1 year post-admission.

Results: A total of 23 patients were included: 17 male and 6 female. As many as 69.5% were diabetic and 91.3% received steroids during COVID-19 treatment. The majority presented within 4 weeks of COVID-19 diagnosis. The CT and MRI findings guided management. In all 23 patients, mucormycosis was confirmed based on biopsy reports, but 4 had overlapping *Aspergillus* infection. All patients were started on amphotericin B and followed up for disease-free status and survival up to 1 year. We also monitored CRP levels to determine the disease-free status.

Conclusions: Immune dysregulation associated with COVID-19, together with unmonitored steroid use, was a major contributor to the increase in mucormycosis cases. We now know that successful treatment of mucormycosis requires early diagnosis, reversal of underlying predisposing risk factors, surgical debridement, and prolonged antifungal therapy

KEYWORDS: amphotericin B, COVID-19, mucormycosis, risk factors, sinusitis

STRESZCZENIE:

Wprowadzenie: Mukormykoza to zagrażające życiu zakażenie wywoływane przez grzyby należące do rzędu *Mucorales*. W charakterze głównych patogenów odpowiedzialnych za zakażenia grzybicze u osób z COVID-19 zgłaszano rodzaje *Aspergillus* i *Mucormycetes*. Do głównych czynników ryzyka należą niewyrównana cukrzyca i przyjmowanie sterydów.

Cel: Celem niniejszego badania była analiza wskaźników diagnostycznych, protokołów leczenia i podejścia do obserwacji kontrolnej u pacjentów dotkniętych mukormykozą po przebytym COVID-19.

Materiał i metody: Do badania włączono pacjentów przyjmowanych do szpitali Medicover z objawami ostrego zapalenia zatok. Informacje gromadzone za pomocą ustrukturyzowanego formularza obejmowały: dane demograficzne, wywiad medyczny, liczbę dni od rozpoznania COVID-19 oraz objawy w obrębie

oczu, nosa i jamy ustnej. Odnotowano wyniki badań obrazowych technikami rezonansu magnetycznego (MRI) i tomografii komputerowej (TK) oraz przeanalizowano parametry krwi, takie jak całkowita liczba leukocytów (TLC), poziom białka C-reaktywnego (CRP), odczyn Biernackiego oraz stężenie hemoglobiny glikowanej i kreatyniny. Pacjentów podzielono na podstawie stadiów choroby i poddano odpowiednim zabiegom chirurgicznym z towarzyszącą terapią przeciwgrzybiczą. Obserwację kontrolną w kierunku choroby resztkowej lub nawrotowej oraz przeżycia prowadzono przez okres 1 roku od momentu wyjściowej hospitalizacji.

Wyniki: Do analizy włączono w sumie 23 pacjentów – 17 mężczyzn i 6 kobiet – z których 69,5% miało rozpoznaną cukrzycę. U 91,3% pacjentów w leczeniu COVID-19 stosowano sterydy. U większości pacjentów prezentacja miała miejsce przed upływem 4 tygodni od rozpoznania COVID-19. Planowany przebieg leczenia wyznaczano na podstawie wyników badań obrazowych technikami TK i MRI. W wyniku analiz bioptatów u wszystkich 23 pacjentów potwierdzono mukormykozę; u 4 osób stwierdzono również nakładające się zakażenie grzybami z rodzaju *Aspergillus*. U wszystkich pacjentów wdrożono leczenie amfoterycyną B, po czym prowadzono obserwację kontrolną w kierunku stanu wolnego od choroby i przeżywalności w okresie 1 roku. W celu stwierdzenia stanu wolnego od choroby monitorowano również poziomy CRP.

Wnioski: Główną przyczyną wzrostu zachorowań na mukormykozę było słabe i upośledzone funkcjonowanie układu odpornościowego spowodowane zakażeniem COVID-19 wraz z niemonitorowanym stosowaniem sterydów. Obecnie wiadome jest, że skuteczne leczenie mukormykozy wymaga: wczesnej diagnozy, odwrócenia podstawowych czynników ryzyka, chirurgicznego oczyszczenia rany i długotrwałej terapii przeciwgrzybiczej.

SŁOWA KLUCZOWE: amfoterycyna B, COVID-19, czynniki ryzyka, Mucormykoza, zapalenie zatok

ABBREVIATIONS

AIDS – Acquired Immunodeficiency Syndrome
AKI – acute kidney injury
CAM – COVID-associated mucormycosis
CNS – Central Nervous System
COVID-19 – Coronavirus Disease 2019
CRP – C-reactive protein
CT – computed tomography
CT PNS – CT scan of paranasal sinuses
ECIL-6 – European Conference on Infections in Leukemia – 6th edition
ECMM – European Confederation of Medical Mycology
ENT – ear, nose, and throat
ESCMID – European Society of Clinical Microbiology and Infectious Diseases
ESS – endoscopic sinus surgery
ICMR – Indian Council of Medical Research
IV – intravenous
KOH – potassium hydroxide
MRI – magnetic resonance imaging
OPD – Outpatient Department
PNS – paranasal sinuses
RFT – renal function test
ROCM – rhino-orbito-cerebral mucormycosis
SBO – skull base osteomyelitis
TLC – total leukocyte count
WHO – World Health Organization

INTRODUCTION

Coronavirus disease 2019 (COVID-19) was declared a global pandemic by the World Health Organization (WHO) in March 2020. Just when India was trying to achieve stability over the situation, COVID-associated mucormycosis (CAM) took over India like a storm [1]. During the second wave, the incidence of mucormycosis was rising rapidly, with 14,872 cases as of May 28, 2021. According to various sources, India accounted for almost 71% of reported global cases of mucormycosis. Even before this, the incidence of mucormycosis in India was as much as 70 times higher than the global average [2].

Mucormycosis is described as a life-threatening infection caused by fungi belonging to the order *Mucorales*. Although these fungi are typically harmless in immunocompetent hosts, fungal infection can rapidly spread in people with low immunity [1]. Aspergillosis and mucormycetes were reported as the principal fungal pathogens in CAM. Infection spreads rapidly by angioinvasion, with rhino–orbital–cerebral and pulmonary manifestations being the most common forms of disease. The conditions facilitating Mucorales spores germination in COVID-affected individuals include the optimum environment of low oxygen, high glucose levels, and reduced phagocytic activity due to immune suppression [2].

Mucormycosis is characterized by host tissue infarction and necrosis resulting from angioinvasion of hyphae. The risk factors include uncontrolled diabetes mellitus, steroid use, extremes of age, neutropenia, AIDS, and iron overload in patients [3]. The 3 subtypes of mucormycosis are rhinomaxillary, rhino-orbital, and rhino-orbito-cerebral mucormycosis (ROCM). The patients typically present with the signs and symptoms of the nasal, facial, palatal, orbital, and/or cerebral regions. Rhizopus is the predominant pathogen, accounting for 90% of the cases of ROCM [4].

Mucormycosis is difficult to manage mainly due to 3 reasons:

1. diagnosis is challenging: mucormycosis shows clinico--radiological similarities with invasive aspergillosis, making early differentiation (which comes with experience) essential;
2. there is no specific, accurate diagnostic tool to confirm the diagnosis: despite their deadly nature, the field of mycology has suffered from inadequate investment in research and therapies over many decades. There is no serological test or serum biomarker available to enable an early diagnosis of mucormycosis.

INDEX COPERNICUS INTERNATIONAL

As a result of this chronic neglect, clinicians remain limited bythe lack of reliable, early diagnostic and treatment tools;

3. mucormycosis requires emergency treatment combining medical and surgical procedures [5]. Even after a diagnosis is made, management is challenging since the disease is spreading fast. Extensive surgical debridement of necrotic tissue is required to give the patient a chance at survival. The mainstay of antifungal treatment is amphotericin B, a nephrotoxic polyene antifungal. Liposomal formulations have reduced toxicity but are costly or are just not available in many settings. Few alternatives are available, like posaconazole and isavuconazole, which are also out of reach due to their cost.

This epidemic within the pandemic of COVID-19 in India has made us aware of the seriousness of fungal infections and the difficulties with their diagnosis and treatment. Early administration of antifungal agents, aggressive debridement of all infected/necrotic tissue, use of various modalities of treatment, including the 2 newer azoles (posaconazole and isavuconazole), and switching to liposomal amphotericin B, if available, remains the mainstay of treatment according to the recently published guidelines by the European Conference on Infections in Leukemia (ECIL-6), as well as those published by the European Society of Clinical Microbiology and Infectious Diseases (ESCMID)/European Confederation of Medical Mycology (ECMM) [6].

AIM

We aim to present a case series, highlighting the clinical and radiological findings, and to propose an adequate management protocol for CAM.

MATERIAL AND METHODOS

This study was conducted on patients who presented between May 2021 and May 2022 to Medicover Hospitals, HiTech City, Hyderabad. All patients who were post-COVID and had symptoms of acute sinusitis with a history of steroid use and ventilator support during COVID-19 treatment were included in the study and subjected to further investigations. Data was collected using a survey instrument, i.e., a structured proforma which included patient demographic details, COVID-19 and vaccine status, and days of presentation from COVID-19 diagnosis.

A total of 32 patients presented with symptoms in the nose, eye, face, cheek, and jaw regions post-COVID. The affected individuals typically present with features of acute sinusitis, like fever, nasal congestion, purulent nasal discharge, and severe headache, but all patients in our study initially presented with only nasal congestion with or without discharge and generalized headache. Other reported symptoms included diplopia, blurring of vision, and jaw pain. Past medical and medication history, as well as comorbidities like diabetes and hypertension, were recorded.

On outpatient endoscopic examination, only a few cases showed classic necrotic tissue with foul-smelling discharge (Fig. 1.).

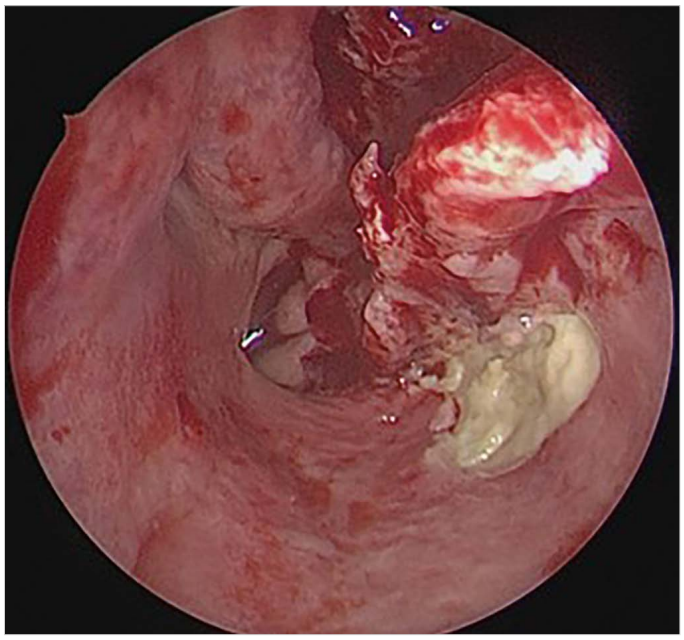

Fig. 1. On endoscopy, necrosis of the floor and medial wall of the maxillary sinus.

Endoscopy mainly showed congested nasal mucosa, thick purulent yellow/green nasal discharge coming from the sinus openings, and, in a few cases, friable mucosa around the middle meatus. As per protocol, we sent nasal swab samples from all patients for potassium hydroxide (KOH) mount to detect the presence of fungal hyphae from nasal mucosa scrapings. In almost 80% of our cases, the KOH mount was positive for fungal hyphae. Hence, those patients were immediately started on intravenous (IV) amphotericin to avoid disease progression.

All suspected cases underwent a computed tomography scan of paranasal sinuses (CT PNS) as the primary investigation. Whenever CT PNS showed suspicious findings, we obtained paranasal sinuses (PNS), orbit, and brain magnetic resonance imaging (MRI) with contrast. Interestingly, very few computed tomography (CT) scans showed bony erosion (Fig. 2.) as expected in classic invasive fungal sinusitis, hence MRI with contrast was needed in almost all cases. The patient who had typical ocular or facial pain but demonstrated only mucosal edema in CT, was diagnosed with MRI whose findings were suspicious for an invasive fungal etiology. MRI signal intensity of the lesion after gadolinium contrast administration was variable. The contrast-enhanced T1-weighted imaging was most useful in detecting devitalized necrotic tissue as non-enhancing lesions [7, 8], namely, the classic black turbinate sign (Fig. 3.) [8]. MRI with contrast also helped in surgical planning. The areas which enhanced with contrast improved with antifungal drug infusion, but the areas that did not take up contrast were dead tissues that should be debrided as far as possible. CT scan was the best tool to assess spread in the bony palate, alveolus, and pterygoid plates, but fat-suppressed images in MRI helped to identify spread in the orbit and pterygopalatine fossa.

In general, most national guidelines include controlling diabetes and starting immediate and extensive radiology-guided surgical intervention as the treatment of choice [5]. Hence, our treatment was concentrated on aggressive surgical debridement on an

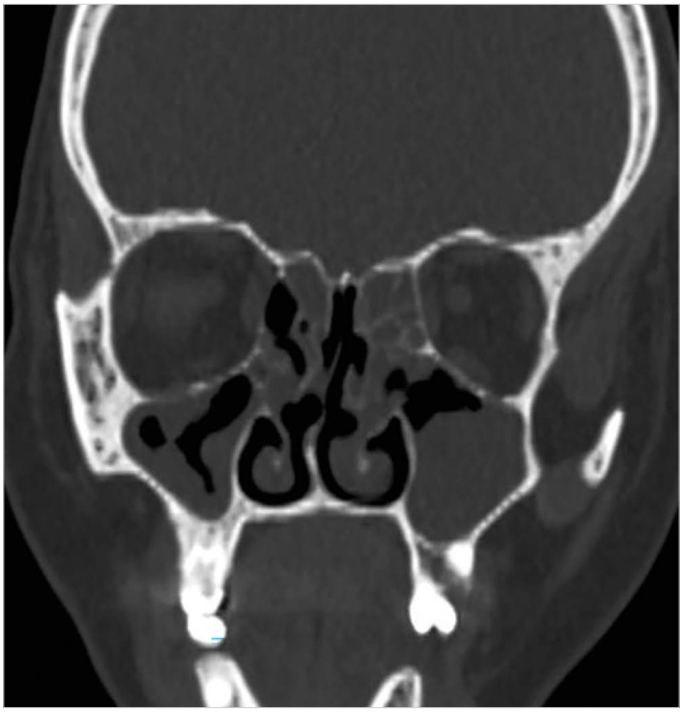

Fig. 2. CT scan showing maxillary and ethmoidal sinusitis, with no bony changes.



Fig. 3. Black turbinate sign (right) on MRI.

emergency basis and simultaneous aggressive medical management with antifungal drugs. Our protocol included rapid control of diabetes, reduction or discontinuation of steroids if the patient was on any, and antifungal therapy, in which amphotericin B was the lifesaving drug of choice for mucormycosis; surgical removal of necrotic tissue, debridement, and enucleation of the eye, if involved, had an equally important role.

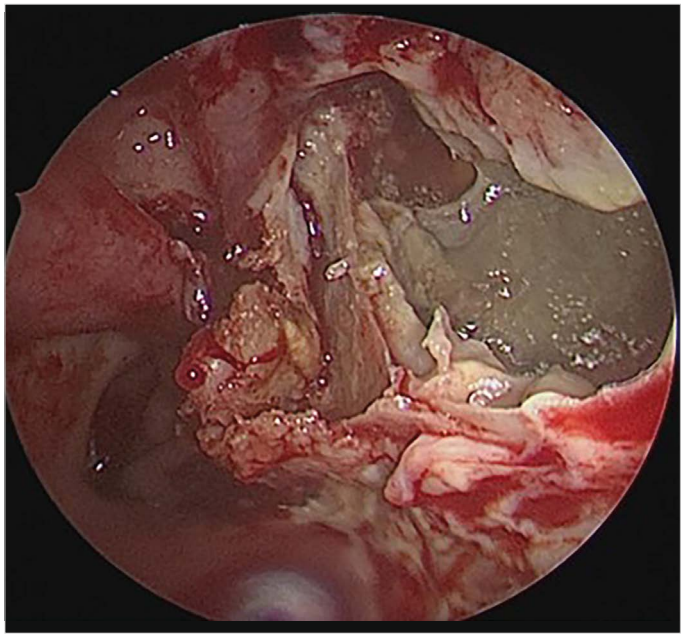

Fig. 4. After wide maxillary antrostomy, entire sinus filled with necrotic tissue.

According to the Indian Council of Medical Research (ICMR) guidelines, antifungal therapy must be administered for at least 4 to 6 weeks [9]. Slow infusion of liposomal amphotericin B (5 mg/kg/day) is the drug of choice, and a higher dose of up to 10 mg/kg/day is recommended if the infection has systemic spread. Deoxycholate and lipid complex forms are alternatives [10]. In our cases, the maximum duration of IV therapy was 45 days, with doses being as high as 7 mg/kg/day when required, and in cases of intracranial spread, about 10 mg/kg/day. They were all monitored clinically through renal function tests (RFTs), blood electrolytes and CRP values, as well as regular endoscopic evaluations. Patients were also put on oral posaconazole for a minimum of 1 month to a maximum of 4 months after discharge from hospital.

In our study, out of the 32 patients who presented to us, only 28 were diagnosed with fungal sinusitis. Among those 28 patients, 5 had extensive cerebral involvement on imaging, with multiple comorbidities, hence, they were not operated on. Only 23 patients underwent surgery. They all first had routine endoscopic sinus surgery (ESS), during which maximum debridement of all necrotic tissue in the nose was done (Fig. 4.), after which 12 of them required revision surgeries. Revision surgeries included maxillectomy (unilateral/bilateral) in 9 patients, and orbital exenteration in 3 patients. Hence, complete removal of infected areas along with early antifungal therapy and close follow-up maybe significantly improved the survival in our study, compared to general morbidity and mortality rates of mucormycosis. Reported mortality is between 17–51% overall and between 30–50% in rhino-orbital cases [6]. Larger comparative studies are required to validate this approach.

Those patients were followed up post-discharge for a minimum of 3 months and a maximum of 6 months in certain cases. Follow-up was once weekly for an initial month in all post-operative patients, with endoscopy done and blood inflammatory markers checked. Patients with a minimal grade (I and II) were called once monthly for 3 months, and patients with a higher

grade (III and IV) were called once weekly, depending on their symptoms and comorbidities. If they were unable to come to hospital due to the distance from their hometown, keeping in mind the ongoing COVID-19 waves, they were monitored by teleconsultation for complaints of any major symptoms. If anyone had recurring symptoms, like headache, foul-smelling discharge from the nose, blurring of vision, numbness in facial areas, they were immediately asked to return to hospital. First three months the patient were followed up every week to check the disease-free status, vision status, residual disease or recurrence of disease. After being declared disease free, they were asked to come to hospital every 6 months for up to 1 year to know their survival. As there are no fixed guidelines for follow-up on mucormycosis, we felt that knowing the disease-free status of our patients in times of COVID-19 was important, with movement being severely restricted.

RESULTS

Statistical analyses were performed using StatSoft Statistica (version 13.0, TIBCO Software Inc., Palo Alto, CA, USA). Continuous variables were expressed as mean ±standard deviation (SD). Comparisons between groups were performed using the Mann–Whitney U test. A p-value < 0.05 was considered statistically significant. Out of 32 patients who presented to the Outpatient Department (OPD), only 23 patients, who were operated on, were studied in detail. Our study showed that mucormycosis was more common among male patients (17, 73.9%) than among female patients (6, 26.0%). Disease was commonly present in the age group of >50 years (65.2%), followed by 40–50 years (21.7%), and least common in the age group of 20–40 years (13.04%).

A total of 13 patients had symptoms related to the nose and sinuses, and 10 had presenting symptoms related to the eye. Most of them had overlapping symptoms. The individual symptoms are shown in Tab. I.

Hyperglycemia (pre-existing/new-onset due to steroid therapy) was the most important risk factor observed; 69.5% of patients were diabetic. The history of corticosteroid intake for the treatment of COVID-19 was present in 21 (91.3%) patients, and only 2 of them required oxygen/ventilator support during COVID-19. The majority (14) presented with symptoms within 4 weeks of COVID-19 diagnosis.

All the patients, after admission, underwent routine blood tests, and their total leukocyte count (TLC), C-reactive protein (CRP) levels, potassium and creatinine were monitored regularly during their treatment and even after discharge. All these patients underwent CT and MRI, and were then staged according to radiologic findings, as depicted in Tab. II. This staging system was adapted from the staging system described by Honavar et al. and Malhotra et al. [10, 11]. Based on the Tab. II., 4 patients (17.3%) were in stage II, 11 (47.83%) were in stage III, and 8 (34.78%) were in stage IV.

All 23 patients underwent surgery, with the primary surgery being ESS for debridement, and revision surgery, if necessary, (n = 12) to deal with the spread of disease to the palate, eye, and skull base.

Tab. I. Presenting symptoms*.

CLINICAL SYMPTOMS	NO. OF PATIENTS
Nasal congestion	8
Headache	8
Facial swelling	6
Jaw pain	8
Blurring of vision/Diplopia	6
Proptosis	3
Loss of vision	2

*Majority patients had overlapping symptoms.

Tab. II. Staging based on radiological findings*.

STAGE	RADIOLOGICAL FEATURES
I	Findings limited to the nasal cavity mucosa.
II	Disease going beyond nasal cavity: a. unilateral sinus; b. bilateral sinus.
III	Disease involving the adjacent structures: a. orbit; b. palate, pterygopalatine fossa (PPF), infratemporal fossa (ITF).
IV	Disease spread to the Central Nervous System: a. extra dural, i.e., only meningeal involvement; b. intracranial, i.e., brain abscess, brain infarcts.

*This system was made by us in reference to other staging systems proposed, to help us plan further management.

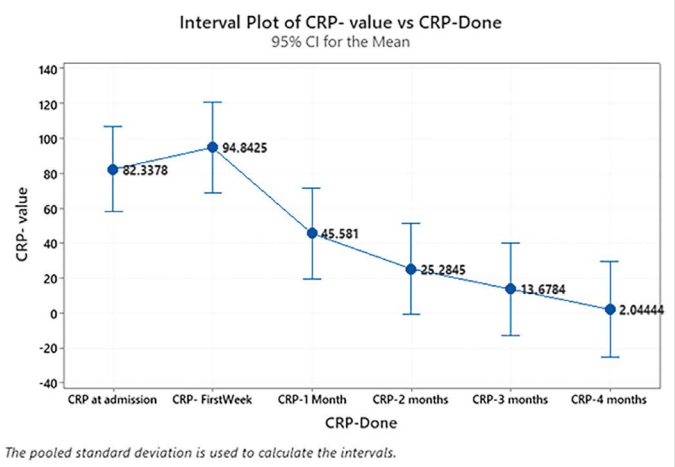

Fig. 5. Variations in CRP levels at different time intervals of treatment.

Based on multiple biopsies from various sites in the nose and PNS, all 23 had a confirmed diagnosis of mucormycosis; however, 4 (17.3%) of them had an overlapping infection with *Aspergillus* as well.

To assess disease remission, we followed the CRP levels as an inflammatory marker, serially for all patients at admission, 1 week after treatment was started, and between 1 and 4 months after their discharge. We noticed that the mean CRP gradually reduced from the time of admission to 4 months after starting treatment. The CRP values were significantly high at admission ($p = 0.01$) and first week ($p<0.001$) when compared the values at 4 months, which was when the disease was in remission (Fig. 5.).

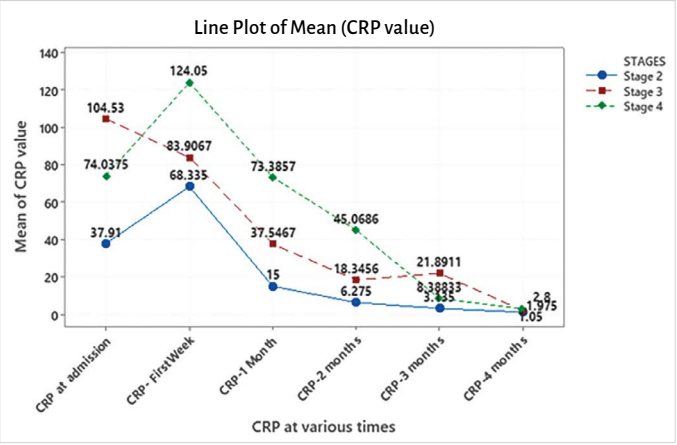

Fig. 6. Mean CRP values compared between different stages at different time intervals of treatment.

CRP values were also compared between stages. Even though the CRP levels were lower in stage II when compared with stage III and stage IV, there were no significant differences between the various stages in terms of CRP levels. CRP at various times for different stages shows that the CRP value at admission is significantly high in stage III and stage IV ($p = 0.05$) (Fig. 6.).

Patients with sinus disease (Stage II) were treated with IV amphotericin for a minimum of 2 weeks, and with oral posaconazole after discharge, while patients with an extrasinonasal disease (Stage III and IV) were given IV amphotericin for a minimum of 1 month and oral posaconazole for 2 months after discharge. Cases with skull base involvement were advised to undergo treatment with IV amphotericin for 6 to 8 weeks, followed by 3 months of oral posaconazole.

The immediate post-operative follow-up protocol included a routine endoscopic checkup and cleaning once a week for the first month, followed by once a month, depending on symptoms and clinical progress. Repeat CT was advised wherever new onset symptoms suggested bony involvement around the hard palate, zygoma, skull base, etc. Repeat MRI was done in case of orbital or cerebral involvement, i.e., stage III and stage IV. Disease-free status was defined by 3 criteria: no new clinical symptoms/findings, no new radiological findings, and CRP levels back to normal.

At last follow-up, 20 patients were disease-free. Out of these 20, 1 died after 3 months of being disease-free due to myocardial infarction. One patient had a relapse around the clivus after 6 months of being declared disease-free and underwent re-debridement and became disease-free thereafter. Only 2 patients died due to the extensive spread of infection to the orbit and Central Nervous System (CNS) within 1 month and 1 was lost to follow-up.

A detailed master chart is provided in Tab. III. for reference and follow-up details.

DISCUSSION

India was going through a major surge of COVID-19 cases during the second wave. Along with this, India was also experiencing an outbreak of mucormycosis, which was affecting thousands of post-COVID patients. Though mucormycosis is a known disease entity in India, with the reported prevalence being 14 per 100,000 in the pre-COVID era, now with a prevalence of almost 27 per 100,000 population [2], it has been a public health concern. It was declared as a notifiable disease by the central government, in accordance with the Epidemic Diseases Act of 1897 [2]. Many Indian states and union territories, including Telangana, declared black fungus an epidemic. One of the strongest associations identified was corticosteroid use among COVID-19 patients. Our study also highlighted the same, as we had almost 91% of patients with a history of steroid usage during COVID-19. Another factor for the outbreak of mucormycosis in Indian patients was poorly controlled diabetes or de novo hyperglycemia during COVID-19 infection. Hyperglycemia, along with steroid use during viral infection, caused a transient immunosuppressed state in patients, which allowed the invasive fungus to grow to such an extent [7]. Out of the 23 patients included in our study, almost 70% were diabetics.

The mean time interval between the diagnosis of COVID-19 and the appearance of symptoms suggestive of mucormycosis was 15.1 ±6.2 days. The affected individuals usually present with acute sinusitis features like fever, nasal congestion, purulent nasal discharge, and severe headache. But all patients in our study presented initially with only nasal congestion and a generalized headache ($n = 8$, 38.09%).

On endoscopic examination, surprisingly, the classic blackening of the nasal mucosa with necrosis of tissues was not seen. Extension of the infection beyond the PNS was observed in 82% of patients (n = 19) as early symptoms were often ignored due to their mild nature. The KOH mount was a useful initial screening test that supported early initiation of therapy for fungal infection, as mucormycosis was proven only on deep tissue and bone biopsy specimens.

In general, most national guidelines include controlling diabetes and starting immediate and extensive radiology-guided surgical intervention as the treatment of choice [2]. Hence, our treatment was concentrated around aggressive surgical debridement on an emergency basis and simultaneous aggressive medical management with antifungal drugs. Our protocol was rapid control of diabetes, reduction or discontinuation of steroids, antifungal prophylaxis, in which amphotericin B was the lifesaving drug of choice for mucormycosis, and surgical removal of necrotic tissue, debridement, and enucleation of the eye, if involved.. However, despite being one of the largest pharmaceutical hubs globally, we lacked amphotericin B in India [1].

Hence, we resorted to using whatever type was available, be it conventional, liposomal, or lipid complex, and newer antifungals were explored, like posaconazole and isavuconazole.

The major challenges during long-term antifungal therapy and revision surgeries were the financial burden on patients and drug--related adverse effects. The most common adverse effect was hypokalemia, severe thrombophlebitis and infusion-related chills. Many patients required central venous access for a long time due to these reasons. Some of them developed acute kidney injury (AKI) too. Hence, they were given drug holidays and doses were modified as

INDEX COPERNICUS INTERNATIONAL

Tab. III. Master chart.

SI. NO	STAGES	SURGERY			MEDICAL MANAGEMENT		BIOPSY	FOLLOW-UP	DISEADE FREE
		Primary	Revision	Re-revision	Hospital stay (Inj. Ampho B & Posoconazaole)	After discharge (Pososconazole)			
1	Stage IVb	1. ESS (Cerebral spread)	–	–	2 weeks	4 months	Mucormycosis	ICA thrombosis after 1 month of surgery, medical management given, interventional radiologist applied ICA stent. Patient recovered	Yes
2	Stage IVa	1. Total Maxillectomy 2. Orbital Excentration	1. Frontal lobe abscess drainage	–	15 days	2 months	Mucormycosis	Had developed multiple intracranial infarcts and convulsions during stay at hospital	Unknown lost to follow-up
3	Stage IIIa & b	1. ESS (left med max)	1. ESS (Pterygopalatine area)	1. Left Maxillectomy	45 days	2 months	Mucormycosis	Oroantral fistula – healed on its own	Yes
4	Stage IIIa & b	1. B/L Maxillectomy 2. ESS	–	–	15 days	1 month	Mucormycosis		Yes
5	Stage IIIb	1. ESS	1. ESS after 2 weeks of first surg	1. Revision ESS (rostrum and anterior portion of sphenoid removed due to complete necrosis)	45 days	4 months	Mucormycosis		Yes
6	Stage II	1. ESS 2. Medical Maxillectomy	–	–	10 days	1 months	Mucormycosis		Yes
7	Stage IVa	1. ESS 2. Orbital Decomprssio	1. Orbital excenteration + endoscopic clearence 2. Latrogenic CSF leak at cribriform area repaired on table	–	1 months	4 months	Mucormycosis		Yes
8	Stage IIIa	1. ESS	–	–			Mucormycosis	Lost vision in 1 eye	Yes
9	Stage IVb	1. ESS	1. Revision ESS	–	20 days		Mucormycosis		Yes
10	Stage II	1. ESS	–	–			Mucormycosis and Aspergillus		Yes
11	Stage IIIb	1. ESS – med max	1. Left partial Maxillectomy after 1 month of first surgery	–	20 days	2 months	Mucormycosis	Oroantral fistula – healed on its own	Yes
12	Stage IIIa	1. ESS (operated when COVID positive)	1. Orbital excenteration within 1 week	–	1 month		Mucormycosis	Lost to 1 month of follow-up	No
13	Stage IIIb	1. ESS	2. B/L Maxillectomy	–	1 month	3 months	Mucormycosis and Aspergillus		Yes
14	Stage IVa	1. ESS	–	–	45 days	6 months	Mucormycosis	Clival involvement was kept in check	Yes
15	Stage II	1. ESS	1. ESS iatrogenic CSF leak repaired on table	–	20 days	3 months	Mucormycosis and Aspergillus		Yes

Tab. III. cd. Master chart.

SI. NO	STAGES	SURGERY			MEDICAL MANAGEMENT		BIOPSY	FOLLOW-UP	DISEADE FREE
		Primary	Revision	Re-revision	Hospital stay (Inj. Ampho B & Posoconazaole)	After discharge (Pososconazole)			
16	Stage IVb	1. ESS (operated when COVID positive)	1. Orbit Excentration (Intracranial Estension within 1 week)	–			Mucormycosis	Died within 1 month due to multiple brain infarct and aspiration pnuemonia	No
17	Stage IIIb	1. ESS	1. Revision ESS 2. Partial Maxillectomy after 1 month of first surgery	–	1 month	3 months	Mucormycosis		Yes
18	Stage IIIa	1. ESS	1. Revision ESS	–	1 month	3 months	Mucormycosis	Developed orbital apex syndrome which recovered with medical management	Yes
19	Stage IIIb	1. ESS	1. Partial Maxillectomy after 1 month of first surgery	–	2 weeks	1 month	Mucormycosis	Oroantral fistula – healed on its own	Yes
20	Stage IVa	1. ESS	–	–	45 days	4 months	Mucormycosis	Died septicemia	No
21	Stage IIIb	1. ESS 2. Partial Maxillectomy	–	–	–	3 months	Mucormycosis	Died after 3 months of being disease free due to myocardial infraction	Yes
22	Stage IVa	1. ESS	–	–	4 days	4 months	Mucormycosis		Yes
23	Stage II	1. ESS with frontal trephination	–	–	2 weeks	1.5 months	Mucormycosis and Aspergillus		Yes

7 – within 2 weeks of primary surgery, vision was lost; hence, orbital exenteration was done along with disease clearance from the skull base area. CSF leak was detected and repaired on the table.
9 – presented with sudden vision loss on the right side without any signs of eye pain/proptosis. Amphotericin was discontinued within 20 days of surgery. Two weeks later presented with ICA thrombosis without any signs of loss of consciousness or paralysis.
15 – during the second ESS, there was an iatrogenic CSF leak from the frontal region and repaired on the table.
20 – admitted for septicemia and heart failure 2 weeks after surgery. Aggressive medical management was given, and the patient recovered.
23 – underwent ESS and external frontal trephination for the extensive frontal sinusitis.
In 3 patients who underwent ESS, the mucosal biopsy was negative for mucormycosis. After their revision surgery (maxillectomy) the bone biopsy was positive for mucormycosis.

per the nephrologist's advice. Among all IV varieties of amphotericin B, the liposomal variety was better tolerated by patients.

Another challenge we all faced was the requirement of interdisciplinary management, as mucormycosis does not fall under 1 specialty due to the progressive involvement of surrounding structures. As a result, smaller centers without subspecialty support were at a disadvantage. It was very important to balance surgical morbidities and risks versus the role of prolonged antifungal use, especially in skull base involvement. Hence, our decisions in such cases were taken in a team consisting of ENT surgeons, infectious disease specialists, nephrologists, neurosurgeons. What is important, patient and the family preferences were always taken into account.

Unlike in traditional mucormycosis cases, in the post-COVID mucormycosis cases, early changes were very subtle clinically. Therefore, imaging helped in assessing the extent of disease, and was crucial for surgical planning, but MRI also showed only non-specific features during the early stage of the disease, like mucosal thickening, which caused a delay in diagnosis [12]. Therefore, our clinical suspicion played an important role in picking up the cases. For all suspected cases, we used CT PNS as the screening tool. Whenever CT PNS showed suspicious findings, contrast-enhanced MRI of PNS, orbits, and brain was obtained. Empiric IV antifungal therapy was initiated in all suspected cases, with further surgery within a maximum of 1 or 2 days. Literature states a mortality of almost 17–51% from mucormycosis [13], but this aggressive approach and long-term follow-up have helped to achieve a higher survival rate (86%) in our cases. Roden et al. also reported early and aggressive surgery to be associated with a decreased risk of mortality [14].

We noticed that 8 cases had a skull base involvement. Howerver, the literature is divided on the management of fungal skull base osteomyelitis (SBO). One approach is radical debridement with reconstruction, and another approach is to debride only as far as possible without causing much morbidity and continuing long-term high-dose antifungals [15]. SBO is challenging to manage due to fast progressive, unpredictable spread [16]. The clinical presentation is non-specific, with common symptoms including headache, orbital congestion, and cranial nerve palsies [17]. This proves again to the central role of imaging in diagnosing this complication. In our study, out of 8 cases with suspected SBO, only 2 had an

extensive intracranial spread, thanks to our aggressive approach to managing the cases.

Serology tests are less likely to be helpful, but interestingly, the charting of CRP values was of great help to assess the progress of the disease and was taken as one of the markers to declare patients as disease-free. In a study conducted in Gujrat, elevated ferritin levels in some patients were indicative of an elevated level of free iron, which is known to increase the susceptibility to mucormycosis but not to other pathogenic fungi, such as *Candida* or *Aspergillus* [18]. All patients underwent close follow-up. We looked for endoscopy findings: necrotic tissue, foul-smelling discharge, or exposed raw bone not getting cleared with antifungal medications. Those were indications for repeat scans and revision surgery. New-onset pain, numbness, fever episodes with increasing CRP levels were also a sign of infection not resolving, and in those patients a decision was made to continue amphotericin B for a longer duration. We would like to highlight that CT scans often showed edematous mucosa, which is a sign of a healing mucosa, and is not to be confused with recurrence. Hence, for recurrence evaluation, MRI was a better tool along with clinical judgment and endoscopy findings.

This study had several limitations. It was conducted at a single center with a relatively small sample size, which may limit the generalizability of the findings. Therefore, larger studies are required for a complete understanding of treatment protocols. There was variability in antifungal therapy due to reduced drug availability, and 1 patient was lost to follow-up. Additionally, reliance primarily on CRP levels for disease monitoring, without incorporating other specific biomarkers, may limit the precision of disease assessment; hence, new biomarkers are needed specifically to monitor fungal diseases. Finally, the multidisciplinary approach adopted in this study, while effective, may not be feasible in resource-limited or smaller healthcare settings.

CONCLUSIONS

This outbreak has improved clinical preparedness for future cases of mucormycosis. The general population knows about the disease and is more cautious about their symptoms, and the doctors treating severely ill patients should be trained to have a high index of suspicion for this disease. Strict glycemic control should be emphasized, and corticosteroid use should be limited. Surgeons should keep in mind that debridement with repeated endoscopic evaluations, along with administration of amphotericin, is lifesaving, and should be as aggressive as possible. Also, monitoring serological parameters can be useful. As we can see in our study, CRP values were significantly high at admission when compared to CRP values when the disease resolved. In conclusion, early detection, proper surgical debridement, early and adequate dosing, and appropriate duration of antifungal treatment, and, most importantly, long-term follow-up, are the mainstay of management of mucormycosis.

ETHICAL APPROVAL

The study was approved by the Institutional Ethical Committee (decision no. MH/2022/IEC).

REFERENCES

1. Ibrahim A.S., Spellberg B., Walsh T.J., Kontoyiannis D.P.: (2012). Pathogenesis of mucormycosis. Clin Infect Dis., 2012; 54 Suppl 1(Suppl 1): S16–S22. doi: 10.1093/cid/cir865.
2. Singh A.K., Singh R., Joshi S.R., Misra A.: Mucormycosis in COVID-19: A systematic review of cases reported worldwide and in India. Diabetes Metab Syndr. 2021; 15(4): 102146. doi: 10.1016/j.dsx.2021.05.019.
3. Suganya R., Narasimhan M. Karthikeyan V., Janagaraj V.D.: Mucormycosis: A Brief Review. J Pure Appl Microbiol., 2019; 13(1): 161–165. doi: 10.22207/JPAM.13.1.16.
4. Nallapu V., Vuppalapati H.B., Sambhana S., Balasankulu B.: Rhinocerebral mucormycosis: A report of two cases. J Indian Acad Oral Med Radiol., 27: 147–151. doi: 10.4103/0972-1363.167142.
5. Pilmis B., Alanio A., Lortholary O., Lanternier F.: Recent advances in the understanding and management of mucormycosis. F1000Res., 2018; 7: F1000 Faculty Rev-1429. doi: 10.12688/f1000research.15081.1.
6. Cornely O.A., Arikan-Akdagli S., Dannaoui E. et al.: ESCMID and ECMM joint clinical guidelines for the diagnosis and management of mucormycosis 2013. Clin Microbiol Infect., 2014; 20 Suppl 3: 5–26. doi: 10.1111/1469-0691.12371.
7. Mishra Y., Prashar M., Sharma D., Akash, Kumar V.P., Tilak T.V.S.V.G.K.: Diabetes, COVID 19 and mucormycosis: Clinical spectrum and outcome in a tertiary care medical center in Western India. Diabetes Metab Syndr., 2021; 15(4): 102196. doi: 10.1016/j.dsx.2021.102196.
8. Herrera D.A., Dublin A.B., Ormsby E.L., Aminpour S., Howell L.P.: Imaging findings of rhinocerebral mucormycosis. Skull Base., 2009; 19(2): 117–125. doi: 10.1055/s-0028-1096209.
9. Kumar K.S.R., Mufti S.S., Sarathy V., Hazarika D., Naik R.: An Update on Advances in COVID-19 Laboratory Diagnosis and Testing Guidelines in India. Front Public Health., 2021; 9: 568603. doi: 10.3389/fpubh.2021.568603.
10. Honavar S.G.: Code Mucor: Guidelines for the Diagnosis, Staging and Management of Rhino-Orbito-Cerebral Mucormycosis in the Setting of COVID-19. Indian J Ophthalmol., 2021; 69(6): 1361–1365. doi: 10.4103/ijo.IJO_1165_21.
11. Malhotra H.S., Gupta P., Mehrotra D. et al.: COVID-19 associated mucormycosis: Staging and management recommendations (Report of a multi-disciplinary expert committee). J Oral Biol Craniofac Res., 2021; 11(4): 569–580. doi: 10.1016/j.jobcr.2021.08.001.
12. Therakathu J., Prabhu S., Aparna I. et al.: (2018). Imaging features of rhinocerebral mucormycosis: A study of 43 patients. Egypt J Radiol Nucl Med., 49(2): 447–452. doi: 10.1016/j.ejrnm.2018.01.001.
13. Bellazreg F., Hattab Z., Meksi S. et al.: Outcome of mucormycosis after treatment: report of five cases. New Microbes New Infect., 2014; 6: 49–52. doi: 10.1016/j.nmni.2014.12.002.
14. Roden M.M., Zaoutis T.E., Buchanan W.L. et al.: Epidemiology and outcome of zygomycosis: a review of 929 reported cases. Clin Infect Dis., 2005; 41(5): 634–653. doi: 10.1086/432579.
15. Vishnu Swaroop Reddy N., Natti R.S., Radha T., Sharma M., Chintham M.: Skull Base Mucormycosis in an Immunocompetent Patient: A Case Report and Literature Review. Indian J Otolaryngol Head Neck Surg., 2019; 71(1): 140–143. doi: 10.1007/s12070-018-1428-y.
16. Bhalla D., Bhalla A.S., Manchanda S.: Can imaging suggest the aetiology in skull base osteomyelitis? A systematic literature review. Pol J Radiol., 2021; 86: e309–e321. doi: 10.5114/pjr.2021.106470.
17. Mejzlik J., Cerny M., Zeinerova L. et al.: The routes of infection spread in central skull-base osteomyelitis and the diagnostic role of CT and MRI scans. BMC Med Imaging., 2019; 19(1): 60. doi: 10.1186/s12880-019-0331-7.
18. Selarka L., Sharma S., Saini D. et al.: Mucormycosis and COVID-19: An epidemic within a pandemic in India. Mycoses., 2021; 64(10): 1253–1260. doi: 10.1111/myc.13353.