Cochlear Implant Revision Surgery: Risk Factors and Outcomes

Katarzyna Radomska[1AEFG], Michał Mielnik[1BCDF], Klaudia Górnostaj[2E], Alicja Chańko[1B], Patrycja Mickiewicz[3B], Renata Twardowska[1B]

[1]Department of Otolaryngology, Pomeranian University of Medicine, Szczecin, Poland
[2]SKN "Kolar", Department of Otolaryngology, Pomeranian University of Medicine, Szczecin, Poland
[3]WSB University, Dabrowa Gornicza, Poland

ABSTRACT:

Introduction: At the Department of Otolaryngology, USK1 PUM in Szczecin, 205 cochlear implant surgeries were performed between 2008 and 2023 in patients with bilateral profound sensorineural hearing loss. Reimplantation was necessary in 8 cases, 3 of which were primarily operated on outside our clinic. The re-implantation rate at the local centre is 2.4%.

Aim: The aim of this study was to analyse the reasons for reimplantation and the surgical procedure at the Department of Otolaryngology in Szczecin. In addition, changes in electrophysiological parameters of electrode impedance, transimpedance measurement, and neural response telemetry (NRT) were assessed.

Materials and methods: Electrophysiological tests (impedance and NRT) were measured before and after the reimplantation procedure, followed by statistical analysis of the changes in the values of the collected measurements.

Results: Reasons for reimplantation comprised: tip fold-over n = 2, extrusion of the implant n = 2, recurrent mastoiditis n = 1, recurrent chronic otitis media with cholesteatoma n = 1, failure of the internal part of the device n = 2. Healing was normal in all patients. Analysis shows that reimplantation leads to a change in impedance. The variability between patients is very significant. In contrast, for NRT, all patients had a decrease in recorded values or no change, but the variation in effect between patients was not significant, allowing the general conclusion that reimplantation typically causes a decrease in NRT values.

Discussion: Given the observed changes in NRT and impedance values in patients after reimplantation surgery, each patient should be treated as newly implanted during the activation of the cochlear implant speech processor.

Conclusions: Surgical re-treatment was successful in all cases. Post-treatment follow-up has shown that reimplantation allows continued successful use of the cochlear implant system.

KEYWORDS: cochlear implant, impedance, neural response telemetry, reimplantation, sensorineural hearing loss

ORIGINAL ARTICLE

Received: 13.03.2025
Accepted: 19.08.2025
Published: 00.00.2025

CITE THIS ARTICLE AS:
Radomska K., Mielnik M., Gornostaj K., Chanko A., Mickiewicz P., Twardowska R.: Cochlear Implant Revision Surgery: Risk Factors and Outcomes; Otolaryngol Pol 2025; 79 (5): 17–24; DOI: 10.5604/01.3001.0055.2531

AUTHORS' CONTRIBUTION:
A. Conceptualization
B. Data Curation
C. Formal Analysis
D. Funding Acquisition
E. Investigation
F. Methodology
G. Project Administration

CORRESPONDING AUTHOR:
Michał Mielnik; Klinika Otolaryngologii Dorosłych i Dzieci i Onkologii Laryngologicznej, Pomorski Uniwersytet Medyczny; ul. Unii Lubelskiej 1, 71-252 Szczecin, Polska;
Tel.: +48 506134440;
E-mail: michal.mielnikk@gmail.com

COPYRIGHT:
Some rights reserved: Polish Society of Otorhinolaryngologists Head and Neck Surgeons. Published by Index Copernicus Sp. z o.o.

OPEN ACCESS:
The content of the journal „Polish Society of Otorhinolaryngologists Head and Neck Surgeons" is circulated on the basis of the Open Access which means free and limitless access to scientific data.

CREATIVE COMMONS CC BY:
This material is available under the Creative Commons – Attribution NonCommercial 4.0 International (CC BY-NC 4.0). The full terms of this license are available on: https://creativecommons.org/licenses/by-nc/4.0/Legalcode

COMPETING INTERESTS:
The authors declare that they have no competing interests.

INDEX COPERNICUS INTERNATIONAL

ABBREVIATIONS

CI – cochlear implant
CT – computed tomography
DF – device failure
NRT – neural response telemetry
TFO – tip fold– over
TIM – transimpedance matrix measurement

INTRODUCTION

Cochlear implant surgery is a safe treatment for patients with profound hearing loss with a low complication rate [1]. However, some patients require reimplantation for various medical and technical reasons [2–5]. Re-implantation of cochlear implants is rare due to a number of factors such as technological development, safety of the surgical procedure, use of high-quality materials, individual selection of the implant for the patient, and appropriate follow-up of patients after surgery. This means that cochlear implants remain a long-term rehabilitation solution that rarely needs to be replaced. In analyses of other studies, the average re-implantation rate was 3.2–8% [4, 6–8] and has decreased significantly over the last 30 years [2, 9]. According to studies by other authors, the most common reasons for reimplantation are device failure, medical reasons (e.g., extrusions, infections), and inconclusive failures [3, 4, 6, 10–14]. Surgical treatment can be performed in one or two stages. The two--stage approach is preferred when the cause of reimplantation is an inflammatory process or implant extrusion [15, 16]. Re-implantation can then be carried out in two stages, with initial partial removal of the implant with the electrode cut off and left in the mastoid cavity due to the need for the skin or mastoid cavity to heal after a previous inflammatory process [13]. In the second stage of the operation, the remaining electrode can be removed from the cochlea, and a new electrode can be implanted. Intraoperative problems that can occur during reoperation include osteoneogenesis or fibrosis of the cochlear lumen, which makes re-insertion of the electrode difficult [5].

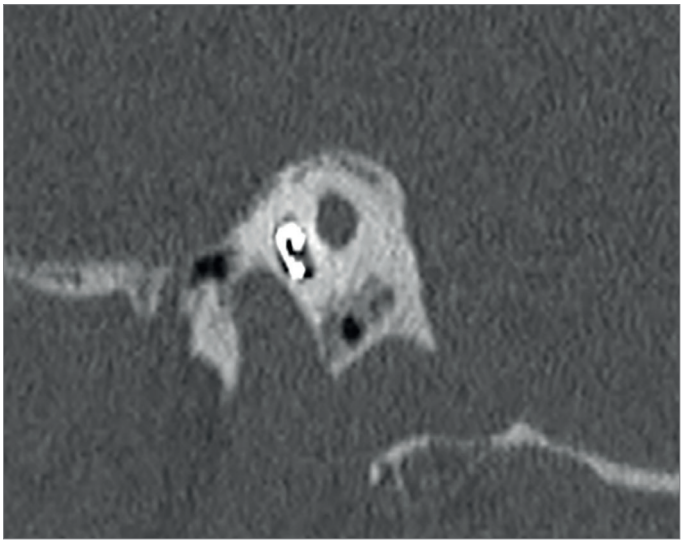

Fig. 1. CT image of the temporal bone in a 58-year-old female patient with a tip fold--over, right side.

AIM

The aim of this study is to analyse the reasons for reimplantation and the surgical management at the Department of Otolaryngology in Szczecin, with an assessment of the changes in electrophysiological parameters after the treatment applied.

MATERIALS AND METHODS

Between 2008 and 2023, 205 cochlear implant surgeries were performed in patients with bilateral profound sensorineural hearing loss, ranging in age from 9 months to 80 years and 2 months. Mean age was 31 years and 3 months, and median 29 years and 7 months. The average local centre reimplantation rate is 2.4%.

Reimplantations were performed in 8 patients, 3 of whom had their first implantation outside our centre. The reasons for cochlear reimplantation were analysed in 8 patients.

In 7 patients, reimplantation was performed with a cochlear implant from the same manufacturer (Cochlear). In 1 case, a patient with osteogenesis imperfecta, the implant model was changed from Advanced Bionics to Oticon.

Electrophysiological measurements were performed in all patients before and after reimplantation: NRT (neural response telemetry), electrode impedance, and transimpedance matrix measurement (TIM). Measurements were performed in patients implanted with cochlear implants using Custom Sound® EP 6.0 software from CochlearTM. Statistical analyses were performed to determine whether there was a decrease or increase in measured impedance and NRT as a result of reimplantation.

Statistical analyses were performed on the electrophysiological measurements obtained - due to data gaps, particularly in the case of the NRT variable, mixed linear models (random effects model) were used. These allow differences in the number of observations between patients to be taken into account. As a result, conclusions about the total patient population can be drawn. Complementary visual analysis methods were used, which in particular provide information on whether there was a significant change for selected (individual) patients (but do not allow inference about the population of all possible patients in this study).

RESULTS

Analysis of the causes of reimplantation

Tab. I. shows the demographics and reasons for reimplantation in the analysed group. The reasons for reimplantation were: tip fold--over n = 2, extrusion of the implant n = 2, recurrent mastoiditis n = 1, recurrent chronic otitis media with cholesteatoma n = 1, failure of the internal part of the device n = 2. The group of eligible patients included 8 patients – 4 adults and 4 children.

The age of the patients ranged from 6 years to 69 years, with the shortest interval between cochlear implantation and reimplantation

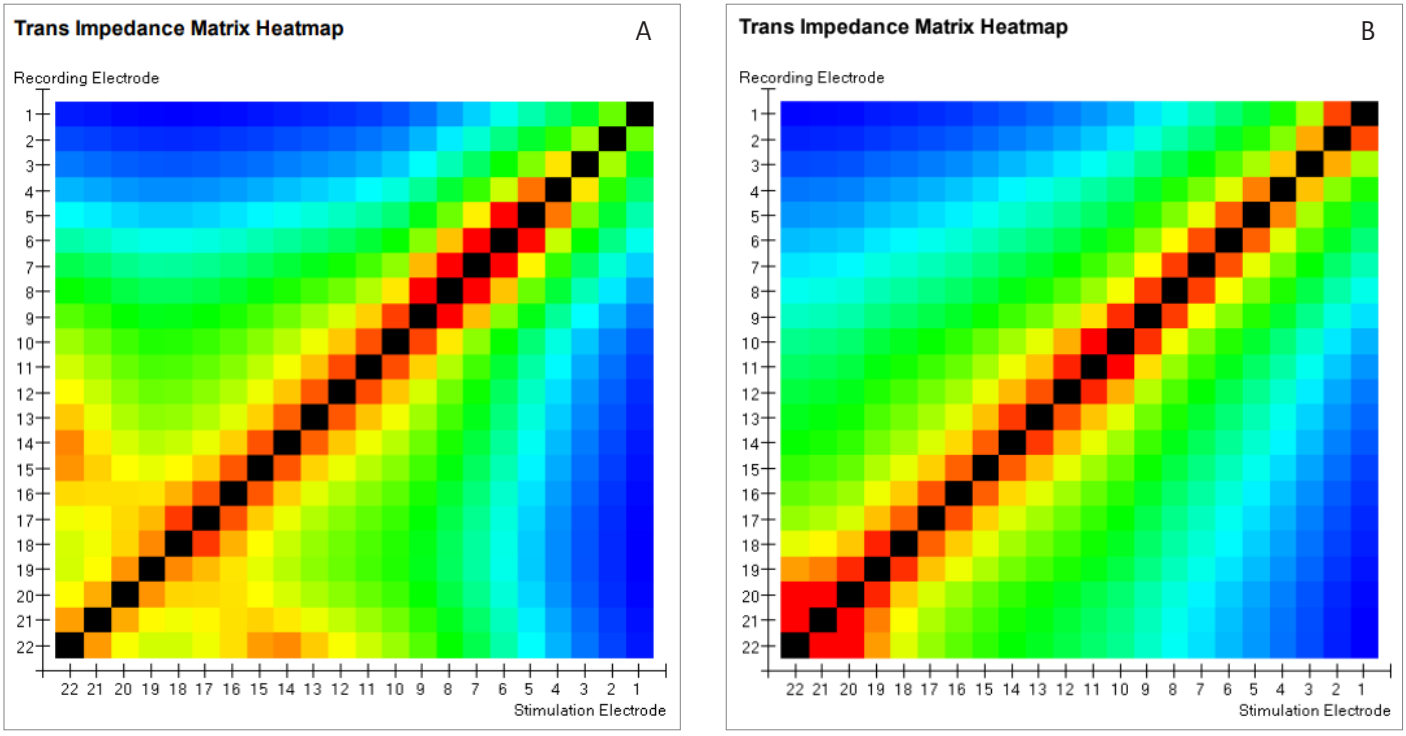

Fig. 2. Heatmap image for transimpedance measurement before (A) and after (B) in a patient with an electrode tip fold-over, Custom Sound® EP 6.0 software from CochlearTM.

Tab. I. Data on reasons for reimplantation and procedure performed.

NO.	GENDER/AGE	PRIMARY IMPLANT CENTER	YEAR OF IMPLANTATION	YEAR OF REIMPLAN-TATION	CAUSE OF REIMPLANTATION	NO. OF STAGES
1.	F/58	Local center	2020	2021	Tip fold-over (TFO)	1
2.	M/69	Local center	2017	2020	Tip fold-over (TFO)	1
3.	F/31	Local center	2020	2021	Implant extrusion	2
4.	M/43	Other center	2003	2023	Implant extrusion	2
5.	F/6	Other center	2016 (Left Ear); 2015 (Right Ear)	2021 (Left Ear)	Recurrent mastoiditis	2
6.	M/12	Other center	2011 (Right Ear); 2015 (Left Ear)	2022 (Right Ear)	Failure of the internal part of the device	1
7.	M/15	Local center	2009	2023	Failure of the internal part of the device	1
8.	M/8	Local center	2014	2017	Recurrence of chronic otitis media with cholesteatoma	1

surgery recorded at seven months in the TFO patient, and the longest recorded at 20 years in the implant extrusion patient. Prior to the surgery, all patients underwent a repeat CT scan. The reimplantation procedure was performed in all cases, with the removal of the previous cochlear implant from the ear that had initially received the implant. In five cases, the reimplantation was performed in a single stage. Two patients with TFO underwent imaging studies and electrophysiological measurements prior to the surgery, which revealed the abnormal position of the electrode in the cochlea (Fig. 1.). This image displays a projection of the right temporal bone, with the electrode hooked at an angle of approximately 180 degrees over a length of approximately 2.5 mm, visible in the projection of the distal part of the basal ganglia of the cochlea. In addition, an atypical transimpedance measurement was obtained during the study. The Custom Sound® EP 6.0 software from CochlearTM was utilised for the study, and a so-called Trans Impedance Matrix Heatmap was performed, which presented an image indicative of an abnormal electrode placement, i.e., TFO (Fig. 2A.). Following the reimplantation, an additional TIM measurement was conducted, resulting in the acquisition of the correct 'Heatmap' image (Fig. 2B.). In both TFO patients, the surgical procedure was executed in a single stage. During the procedure, the implant coil containing the passive electrode and a segment of the active electrode was initially removed. Then the bony overhangs of the cortical layer of the mastoid process were abolished, and the rest of the active electrode was removed. The entrance to the cochlea was then widened, and the implant coil was fixed under the skin, after which the electrode was placed. Impedance and TIM measurements were then performed and correct results were obtained.

In three cases, a two-stage approach was used, initially a partial removal of the implant was performed with the electrode cut off and

INDEX COPERNICUS INTERNATIONAL

Tab. II. Mixed linear model results for impedance change.

Omnibus Test	**F**	**Num df**	**Den df**	**p**			
Reimplantation	1.894	1	5	0.227			
Effect	**Estimate**	**SE**	**Lower 95% CI**	**Upper 95% CI**	**df**	**t**	**p**
(Constant)	10.652	1.398	7.912	13.392	5	7.62	< .001
Reimplantation (*vs* Before)	–2.792	2.029	–6.769	1.184	5	–1.376	0.227
Random components							
Groups	**Name**	**SD**	**Variance**	**ICC**			
Patient	(Constant)	3.417	11.676	0.847			
	Reimplantation	4.95	24.505				
Residuals		1.452	2.107				
n = 262, groups by variable Patient = 6							
LRT for random effect							
Test	**N. pairs**	**AIC**	**LRT**	**df**	**p**		
(1 + Reimplantation | Patient)	4	1295.312	294.327	2	< .001		



Fig. 3. 43-year-old patient with implant extrusion on the left side, with visible migration of the receiving part and skin necrosis over the coil before surgery (A) and after surgery (B).

left in the mastoid cavity, followed by reimplantation on the same side with initial removal of the residual electrode. In two patients, the reason for reoperation was implant extrusion: a 31-year-old woman with congenital bone fragility and a 43-year-old man. In the patient with osteogenesis imperfecta, implant coil migration and wound dehiscence occurred twice due to bone build-up in the cortical layer. The coil migration occurred despite the creation of a deep socket and the attachment of the implant to the cranial bone. The implant coil was then removed, leaving the electrode tip in the cochlea. Reimplantation with an Oticon implant on the same side, with screw fixation, was performed. A male patient presented with an inflammatory lesion in the left supra-auricular region one year prior to the reoperation. The patient observed purulent contents leaking from the lesion. Initially, the cochlear implant on the left side was removed due to a partial migration of the receiving part of the cochlear implant, with skin necrosis over the coil present (Fig. 3A.). This was followed by the reimplantation on the same side (Fig. 3B.).

The third patient who underwent a two-stage reoperation was a 6-year-old girl with recurrent mastoiditis, who had been implanted bilaterally outside the local centre. Her medical history included two episodes of left-side mastoiditis, treated with mastoidectomy and revision of the left ear.

In two cases, the reoperation was required due to a failure of the internal part of the device. These were: a 12-year-old male patient 11 years after the CI surgery, and a 15-year-old male patient 14 years after the CI surgery. The first patient was bilaterally implanted and did not use the speech processor on the right side for a year. The second patient, on the other hand, began to remove the speech processor and expressed dissatisfaction with the results, finding the device unpleasant. Both patients underwent a laryngological examination, which revealed no significant abnormalities. However, a lack of communication between the processor and the CI was identified, and a clinical

Tab. III. Mixed linear model results for NRT change.

Omnibus Test	**F**	**Num df**	**Den df**	**p**			
Reimplantation	8.277	1	134.167	0.005			
Effect	**Estimate**	**SE**	**Lower 95% CI**	**Upper 95% CI**	**df**	**t**	**p**
(Constant)	183.387	10.696	162.423	204.352	4.012	17.145	< .001
Reimplantation (*vs* Before)	–7.676	2.668	–12.905	–2.447	134.167	-2.877	0.005
Random components							
Groups	**Name**	**SD**	**Variance**	**ICC**			
Patient	(Constant)	23.735	563.348	0.715			
Residuals		15.000	224.989				
n = 140, groups by variable Patient = 5							
LRT for random effect							
Test	**N. pairs**	**AIC**	**LRT**	**df**	**p**		
(1 | Patient)	3	1310.071	139.620	1	< .001		
(1 + Reimplantation | Patient)	4	1172.450	3.638	2	0.162		

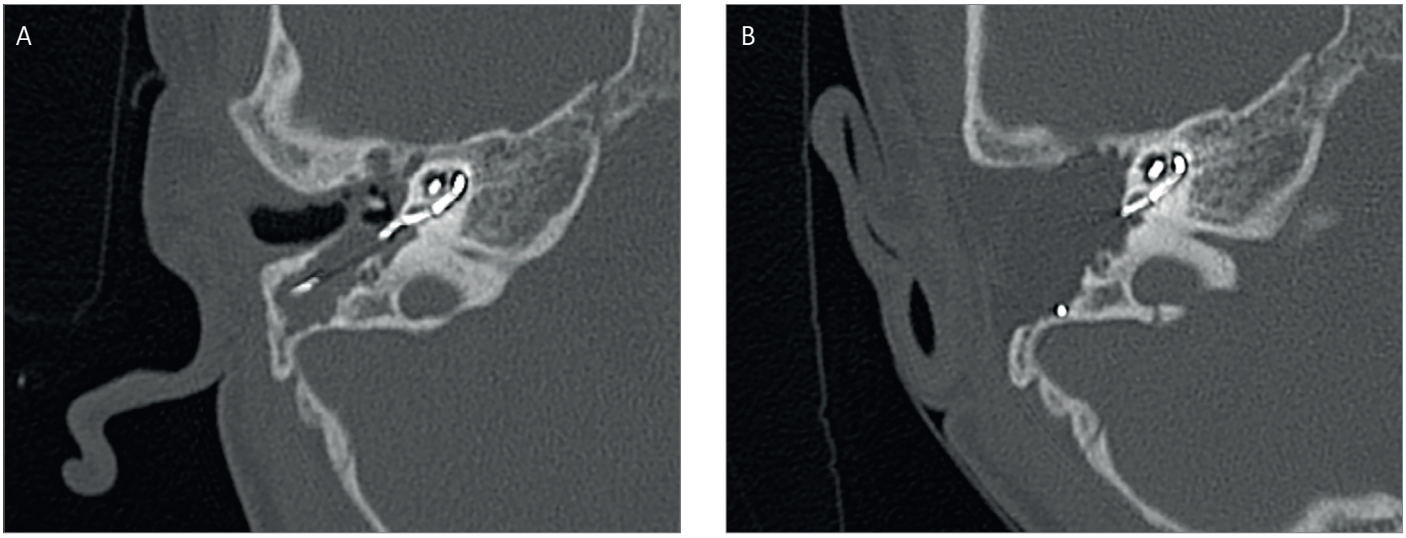

Fig. 4. CT image in a child with recurrence of chronic otitis media on the right side after cochlear implantation (A) and after lateral petrosectomy with reimplantation on the right side (B).

engineer's assessment of the internal part of the CI revealed its malfunction. Reimplantation in both patients was performed in one stage. After the surgery and activation of the processor, the patients accepted the hearing that the new devices provided.

The last patient was a 5-year-old boy with autism, in whom a cholesteatoma was removed during the CI surgery on the right side. Three years after the surgery, a CT scan showed cholesteatoma recurrence after CI implantation with fistulas on the superior wall of the lateral semicircular canal and the anterior wall of the superior semicircular canal (Fig. 4A.). A lateral petrosectomy and reimplantation surgery with perilymphatic fistula provision was performed, and subsequent follow-up CT scans revealed no signs of cholesteatoma recurrence [17]. Fig. 4B. presents a post-operative control CT image, showing the mastoid cavity filled with fatty tissue, the external auditory canal closed, and the electrode in the cochlea. Postoperative observations indicated that the child demonstrated good auditory responses and speech comprehension; however, active speech development was not observed.

Results of intraoperative measurement analysis

As demonstrated in Fig. 5A., a graphical representation of the change in impedance for each patient is provided. A significant change in impedance was observed in four patients, with three cases demonstrating a decrease (patients with TFO, recurrence of chronic mastoiditis with cholesteatoma, recurrent mastoiditis) and one case – an increase (reimplantation due to failure of the internal part of the device). In two patients, the change in impedance was insignificant (implant extrusion and TFO). The overall change in impedance, as depicted in Fig. 5B., reveals a slight decrease in the value following reimplantation.

The results of the impedance change analysis are presented in Tab. II. These results indicate that there are significant differences between patients in impedance change (p random effect Reimplantation|Patient < 0.001), which is consistent with the earlier observation that for some patients the value decreased, and for others it increased or remained the same. There is no basis for concluding that there is an overall change (p fixed effect Reimplantation|Patient = 0.227).

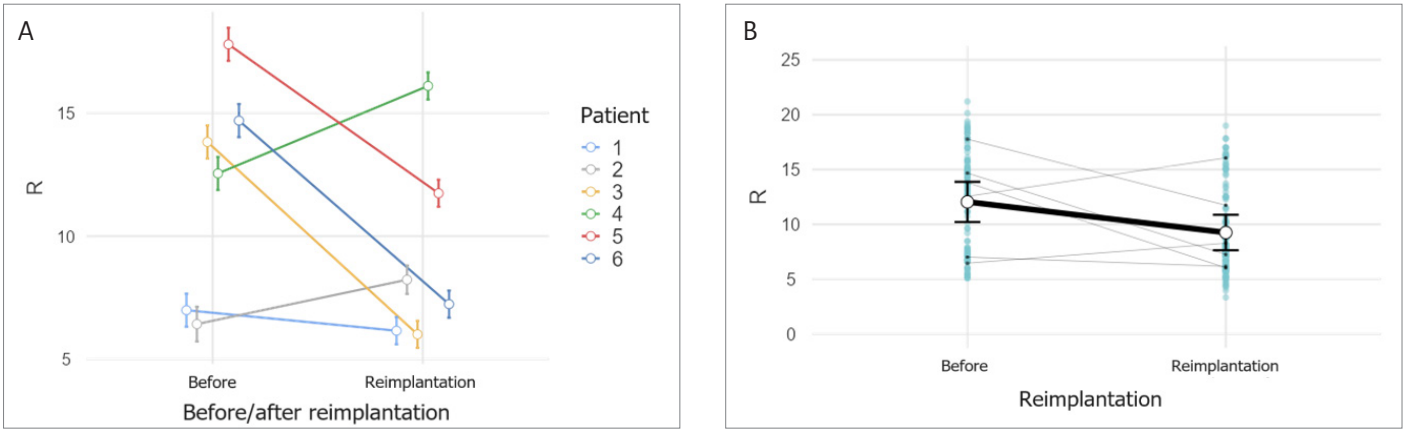

Fig. 5. Graph of mean impedance change for individual patients after reimplantation (A); Graph of overall impedance change after reimplantation based on changes in individual patients (B).

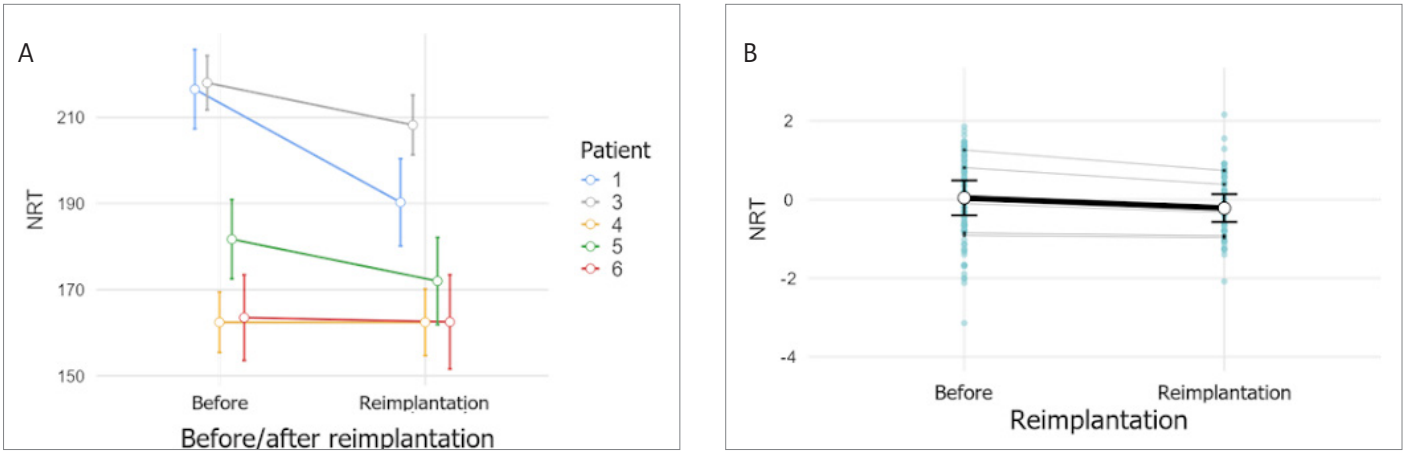

Fig. 6. Graph of NRT change for individual patients after reimplantation (A); Graph of overall NRT change after reimplantation based on changes in individual patients (B).

Fig. 6A. demonstrates a graph showing the change in NRT for individual patients. One patient was completely eliminated due to the fact that no NRT measurements were taken for him at the time of the original implantation (the change in the implant model made it impossible to compare results). The graph shows that for the patients, the NRT value remained the same or decreased following the reimplantation. Fig. 6B. shows a graph of the overall change in NRT, based on all available NRT measurements, with a slight overall change (a decrease of a few units) being observed.

The results of the NRT change analysis are presented in Tab. III. The model indicates that there is a significant generalisable difference in NRT value after reimplantation: the value decreased afterwards ($p = 0.005$). According to the present data, there is no basis to conclude that the effect significantly differs between patients ($p\ \text{Reimplantation}|\text{Patient} = 0.162$).

The analysis indicates that in the case of impedance, reimplantation typically leads to a change in impedance in patients. However, the data so far do not provide a basis for detecting a general pattern according to which this change takes place (systematic decrease or increase). The variability in different patients is very significant. In contrast, the analysis of NRT revealed a decrease or no change in all patients. However, the variation in effect between patients was not significant, allowing the general conclusion that reimplantation typically influences a decrease in NRT values, though the effect was weak, averaging less than 8 units.

DISCUSSION

Patients who have undergone cochlear implant surgery require regular follow-up visits with assessment of the healing process after surgery, so that if abnormalities are found, appropriate treatment can be implemented as soon as possible to avoid re--operation. However, if no other treatment option is available, each case should be assessed individually with surgical or conservative treatment appropriate to the cause of the implant dysfunction. Observation of auditory rehabilitation is equally important; if no progress is made, further diagnostics are indicated to find the cause of the problem. Reimplantation causes can be divided into those related to the implant itself (device failure, TFO) and those related to the inflammatory process around the device (extrusion, mastoiditis, cholesteatoma). In our clinic, if there is an infection around the implant, we immediately use appropriate antibiotic therapy and surgical techniques to remove necrotic tissue or debridement of the wound above the implant. If no abnormalities are observed in the otolaryngological examination, but the patient is not getting the expected benefit from the implant, additional imaging tests and device evaluation are performed to rule out TFO and DF. In

one patient, reimplantation due to TFO occurred 3 years after the CI implantation. During the initial implementation of the Slim Modiolar electrode implant model, imaging studies were performed to detect a possible TFO. However, as also shown in the work of other authors [18], Stenvers examinations are not always sensitive enough, and TFO was not detected immediately after the procedure. In the further post-operative period, the patient would not report for follow-up examinations. After the possibility of transimpedance testing was introduced into Custom Sound and performed in the described patient, TFO was detected, and the patient was qualified for reimplantation.

It is worth noting that electrophysiological examinations have advanced over the past 15 years. Currently, an additional measurement to control the position of the cochlear implant electrode during the implantation is the TIM. The availability and proper interpretation of the TIM measurement improve the detection of implant tip fold-over or improper implantation, without the need for radiological examinations in the operating room [19–23]. Some authors believe that the mere occurrence of a TFO is not an indication for reimplantation, and the results of rehabilitation should be considered first and foremost. If they are satisfactory, then the electrode tip fold-over can be left in place, or possibly the malfunctioning electrode can be turned off [24]. However, it seems that such conclusions apply to centers where intraoperative assessment of electrode position was not performed, and detection of TFO occurred after surgery, and possible interventions required another operation. In our opinion, it is worthwhile to use tools that allow intraoperative diagnosis of TFO so that appropriate intervention can be undertaken during the same surgery [25].

Due to the achieved differences in electrophysiological measurements such as NRT and impedance after reimplantation – each patient should be treated as newly implanted during the speech processor activation. A limitation of the analysis of the presented study is the small size of the study group, but the results obtained suggest that further research is warranted and may lead to interesting conclusions after testing on a larger group of patients. Particularly noteworthy is the reduction in NRT values in patients with a new electrode, which may be indicative of changes within the electrode itself occurring over the years.

It should be noted that reimplantation treatment is safe and effective and does not significantly increase the risk of partial implantation, displacement of the electrodes into the vestibular system, or reduction of the implantation angle of the electrode array [26]. During the procedure, difficulties in the proper placement of the new electrode are possible due to changes in the anatomical structure of the inner ear after the first operation. In one patient suffering from osteogenesis imperfecta, it was decided to change the implant company in the process of the reoperation. During the original implantation, the patient had an AB implant, but due to the migration of the implant as a result of the bone superstructure caused by the patient's condition, an Oticon implant was used, with the processor fixed to the bone with dedicated screws.

CONCLUSIONS

In all cases, the surgical re-treatment was successful, and healing was normal. Post-treatment follow-up showed that the reimplantations did not worsen the patient's hearing outcome compared to the original implantation.

ACKNOWLEDGEMENTS

The authors gratefully acknowledge Andrzej Porębski, who performed the statistical analyses presented in the article, and "Wielka Orkiestra Świątecznej Pomocy" Foundation for providing equipment for cochlear implantation in children.

REFERENCES

1. Farinetti A., Ben Gharbia D., Mancini J. et al.: Cochlear implant complications in 403 patients: comparative study of adults and children and review of the literature. Eur Ann Otorhinolaryngol Head Neck Dis., 2014; 131(3): 177–182. doi: 10.1016/j.anorl.2013.05.005.
2. Balkany T.J., Hodges A.V., Gómez-Marín O. et al.: Cochlear reimplantation. Laryngoscope., 1999; 109(3): 351–355. doi: 10.1097/00005537-199903000-00002.
3. Asghari A., Farhadi M., Daneshi A. et al.: Cochlear reimplantation rate, causes, and outcomes: a multicenter study. Cochlear Implants Int., 2024; 25(6): 1–10. doi: 10.1080/14670100.2024.2448905.
4. Liu H., Yao X., Kong W. et al.: Cochlear Reimplantation Rate and Cause: a 22-Year, Single-Center Experience, and a Meta-Analysis and Systematic Review. Ear Hear., 2023; 44(1): 43–52. doi: 10.1097/AUD.0000000000001266.
5. Côté M., Ferron P., Bergeron F., Bussières R.: Cochlear reimplantation: causes of failure, outcomes, and audiologic performance. Laryngoscope., 2007; 117(7): 1225–1235. doi: 10.1097/MLG.0b013e31805c9a06.
6. Lane C., Zimmerman K., Agrawal S., Parnes L.: Cochlear implant failures and reimplantation: A 30-year analysis and literature review. Laryngoscope., 2020; 130(3): 782–789. doi: 10.1002/lary.28071.
7. Bourdoncle M., Fargeot C., Poncet C., Mosnier I.: Analysis and management of cochlear implant explantation in adults. Eur Ann Otorhinolaryngol Head Neck Dis., 2020; 137(6): 459–465. doi: 10.1016/j.anorl.2020.04.001.
8. Sunde J., Webb J., Moore P., Gluth M., Dornhoffer J.: Cochlear Implant Failure, Revision, and Reimplantation. Otology & Neurotology., 2013; 34(9): 1670–1674. doi: 10.1097/MAO.0000000000000079.
9. Saeed S.R., Ramsden R.T., Hartley C., Woolford T.J., Boyd P.: Cochlear reimplantation. The Journal of Laryngology & Otology., 1995; 109: 980–985.
10. Hwang C.F., Ko H.C., Tsou Y.T. et al.: Comparisons of Auditory Performance and Speech Intelligibility after Cochlear Implant Reimplantation in Mandarin-Speaking Users. Biomed Res Int., 2016; 2016: 8962180. doi: 10.1155/2016/8962180.
11. Olgun Y., Bayrak A.F., Catli T. et al.: Pediatric cochlear implant revision surgery and reimplantation: an analysis of 957 cases. Int J Pediatr Otorhinolaryngol. 2014; 78(10): 1642–1647. doi: 10.1016/j.ijporl.2014.07.013.
12. Hou V., Tellez P., Fandiño M. et al.: Pediatric cochlear implant explantation and reimplantation over a 32-year period. Int J Pediatr Otorhinolaryngol., 2023; 166: 111460. doi: 10.1016/j.ijporl.2023.111460.
13. Ketterer M.C., Shiraliyev K., Arndt S., Aschendorff A., Beck R.: Implantation and reimplantation: epidemiology, etiology and pathogenesis over the last 30 years. Eur Arch Otorhinolaryngol., 2024; 281(8): 4095–4102. doi: 10.1007/s00405-024-08568-2.
14. Aldhafeeri A.M., Alzhrani F., Alajlan S., AlSanosi A., Hagr A.: Clinical profile and management of revision cochlear implant surgeries. Saudi Med J., 2021; 42(2): 223–227. doi: 10.15537/smj.2021.2.25647. Erratum in: Saudi Med J., 2021; 42(4): 458.

15. Leonhard L., Roche J., Wieland A., Pyle G.M.: The Temporoparietal Fascia Flap is an Effective Strategy for Cochlear Implant Wound Coverage. Annals of Otology, Rhinology & Laryngology., 2020; 129(2): 135–141. doi:10.1177/0003489419877429.

16. Antonelli P.J.: Cochlear Implant Infections. Infect Dis Clin North Am., 2024; 38(4): 777–793. doi: 10.1016/j.idc.2024.07.009.

17. Amernik K., Niemczyk K., Twardowska R., Jaworowska E.: Zastosowanie petrosektomii w chirurgii implantów ślimakowych. Pol Otorhino Rev., 2020; 9(2): 1–6. doi: 10.5604/01.3001.0014.1374.

18. Leblans M., Zarowski A., Molisz A. et al.: Cochlear implant electrode array tip-foldover detection by electrode voltage telemetry. Cochlear Implants Int., 2023; 24(2): 95–106. doi: 10.1080/14670100.2022.2148890.

19. Hoppe U., Brademann G., Stöver T. et al.: Evaluation of a Transimpedance Matrix Algorithm to Detect Anomalous Cochlear Implant Electrode Position. Audiol Neurootol., 2022; 27(5): 347–355. doi: 10.1159/000523784.

20. Nagy R., Perényi Á., Dimák B. et al.: Detection of "tip fold-over" of the cochlear implant electrode array with transimpedance matrix (TIM) measurement. Orv Hetil., 2021; 162(25): 988–996. Hungarian. doi: 10.1556/650.2021.32073.

21. Klabbers T.M., Huinck W.J., Heutink F., Verbist B.M., Mylanus E.A.M.: Transimpedance Matrix (TIM) Measurement for the Detection of Intraoperative Electrode Tip Foldover Using the Slim Modiolar Electrode: A Proof of Concept Study. Otol Neurotol., 2021; 42(2): e124–e129. doi: 10.1097/MAO.0000000000002875.

22. de Rijk S.R., Hammond-Kenny A., Tam Y.C. et al.: Detection of Extracochlear Electrodes Using Stimulation-Current- Induced Non-Stimulating Electrode Voltage Recordings With Different Electrode Designs. Otol Neurotol., 2022; 43(5): e548–e557. doi: 10.1097/MAO.0000000000003512.

23. Hans S., Arweiler-Harbeck D., Kaster F. et al.: Transimpedance Matrix Measurements Reliably Detect Electrode Tip Fold-over in Cochlear Implantation. Otol Neurotol., 2021; 42(10): e1494–e1502. doi: 10.1097/MAO.0000000000003334.

24. Gabrielpillai J., Burck I., Baumann U., Stöver T., Helbig S.: Incidence for Tip Foldover During Cochlear Implantation. Otol Neurotol., 2018; 39(9): 1115–1121. doi: 10.1097/MAO.0000000000001915.

25. Radomska K., Talar M., Haber K. et al.: Transimpedance Matrix Measurement (TIM) Parameters Evaluation for the Assessment of Cochlear Implant Electrode Placement and Modiolar Proximity in Children. Biomedicines., 2025; 13(2): 319. doi: 10.3390/biomedicines13020319.

26. Beck R., Shiraliyev K., Arndt S. et al.: Scalar position, dislocation analysis and outcome in CI reimplantation due to device failure. Eur Arch Otorhinolaryngol., 2022; 279(10): 4853–4859. doi: 10.1007/s00405-022-07315-9.